

RELATO DE CASO

FOURNIER'S SYNDROME RECURRENCE: A CASE REPORT
SINDROME DE FOURNIER RECIDIVADA: UM RELATO E CASO

Viviane de Deus Silva¹, Luis Fernando Barbosa Silva¹, João Guilherme Silva de Oliveira¹, Larissa Mendonça Ferreira¹, Pedro Manuel Gonzalez Cuellar².

ABSTRACT

The Fournier's Syndrome is characterized by a necrotizing infection that can affect regions such as perineum, thighs, scrotum, thigh roots and lower abdomen. It begins insidiously, but progresses with great tissue loss and is of difficult handling. It is an uncommon morbidity of the population at large. Recurrence is poorly documented, which makes its occurrence atypical in medical practice. The mortality rate varies from 10% to 30.8% in Brazil without changes over time despite advances in technology and in surgical techniques. The objective of this study is to demonstrate a recurrence of the syndrome in a male, 46-year-old patient, with diabetes, hypertension and grade III obesity. The patient was treated in a timely manner with satisfactory clinical and aesthetic outcomes.

Keywords: Fournier's Syndrome; Debridement; Recurrence.

RESUMO

A síndrome de Fournier caracteriza-se por uma infecção necrozante que pode acometer região perineal, coxa, escroto, raízes de coxa e abdome inferior. Tem seu início insidioso, porém com progressão com grande perda de tecidos e difícil manejo. É uma morbidade incomum da população em geral. A recidiva é pouco documentada tornando-se atípico na prática médica. A taxa de mortalidade varia de 10% a 30.8% no Brasil sem mudança no decorrer do tempo apesar dos avanços tecnológicos e de técnicas cirúrgicas. O objetivo deste estudo é demonstrar uma recidiva da Síndrome em um paciente masculino, 46 anos com diabetes, hipertensão e obesidade grau III. Foi tratada em tempo hábil com bom desfecho clínico e estético.

Palavras-chave: Síndrome de Fournier; Debridamento; Recidiva.

 ACESSO LIVRE

Citação: Silva VD, Silva LFB, Oliveira JGS, Ferreira LM, Cuellar PMG (2019) Fournier's syndrome recurrence: a case report. Revista de Patologia do Tocantins, 6(2): 35-37.

Instituição: ¹Interno de Medicina, Discente da Universidade Federal do Tocantins, Tocantins, Brasil; ²Professor adjunto da Universidade Federal do Tocantins, Especialista em Cirurgia Geral, Coordenador do internato de Urgência e Emergência da Universidade Federal do Tocantins, Tocantins, Brasil.

Autor correspondente: Viviane de Deus Silva; vivianedeussilva@gmail.com

Editor: Guedes V. R. Medicina, Universidade Federal do Tocantins, Brasil.

Publicado: 09 de junho de 2019.

Direitos Autorais: © 2019 Silva et al. Este é um artigo de acesso aberto que permite o uso, a distribuição e a reprodução sem restrições em qualquer meio, desde que o autor original e a fonte sejam creditados.

Conflito de interesses: os autores declararam que não existem conflitos de interesses.

INTRODUCTION

Fournier's Syndrome or Gangrene is a serious soft-tissue polymicrobial infectious disease. It is caused by aerobic and anaerobic microorganisms that act synergistically. These microorganisms cause rapid progression necrotizing fasciitis, affecting mainly the genital, perineal and perianal regions.^{1,2,3,6,7,8}

When not treated early, the process can rapidly extend to the anterior abdominal wall, dorsal region, upper limbs and retroperitoneum and induce sepsis, multiple organ failure, and even death. Thus, early diagnosis along with appropriate and aggressive treatment are determining factors in the prognosis of the patient.^{1,7}

It is a predominantly male pathology^{1,2,5,7,8,9}, between the third and sixth decades of life³, and the presence of associated morbidities is common. In women, it presents itself as a necrotizing infection of the perineum or vulva, and is usually secondary to Bartholin's gland abscesses, episiotomy, hysterectomy, or paracervical and pudendal blocks⁹. It is a relatively uncommon disease.¹

Some systemic diseases are risk factors for the development of gangrene. Diabetes mellitus is highlighted as the main cause of poor treatment results in Fournier's Syndrome^{2,5,6,9}. Alcoholism, hypertension, obesity, smoking, and immunosuppressive diseases and conditions such as HIV infection, radio and chemotherapy, leukemia, among others, are also causes of poor results. In view of the increasing number of cases of HIV infection in population, it is recommended that this infection be searched for in patients who develop gangrene without an apparent causal factor. These cases are related to a worse prognosis.^{1,7}

Representing a public health problem with an incidence of 1 case in 7,500 people, high treatment and rehabilitation costs³, Fournier's Gangrene has high mortality rates^{1,2,7,9}, ranging from 13 to 30.8% in Brazil, reaching in some studies 30% to 50%, increasing to up to 80% in diabetics and the elderly.^{2,7}

CASE REPORT

BSH, 46, male, married, law clerk, from England and residing in Orlando - US. The patient has type II diabetes mellitus, chronic hypertension and obesity grade III. The patient has a previous history of Fournier's Gangrene, which resulted in penile amputation 10 years ago. He sought the Emergency Care Service of the General Hospital of Palmas (HGP), after 30 days of the onset of a pustular lesion in the left inguinal-scrotal region.

Clinically, the patient had severe pain in the left scrotum, with the presence of phlogistic signs. He also presented asthenia and a high fever (measured between 38°C to 40°C) accompanied by sweating and shivering for 1 week.

In a first medical care in another hospital unit, the patient was treated for 14 days with antibiotic therapy (Cephalexin), anti-inflammatories and analgesics, with the diagnosis of furunculosis. After beginning treatment with the medication, the febrile episodes ceased and there was a reduction of the phlogistic signs. However, 4 days after the end of the drug treatment, drainage

of serosanguinolent secretion with fetid odor began. Lesion evolved after 14 days with leakage of fetid whiteish-bloody discharge.

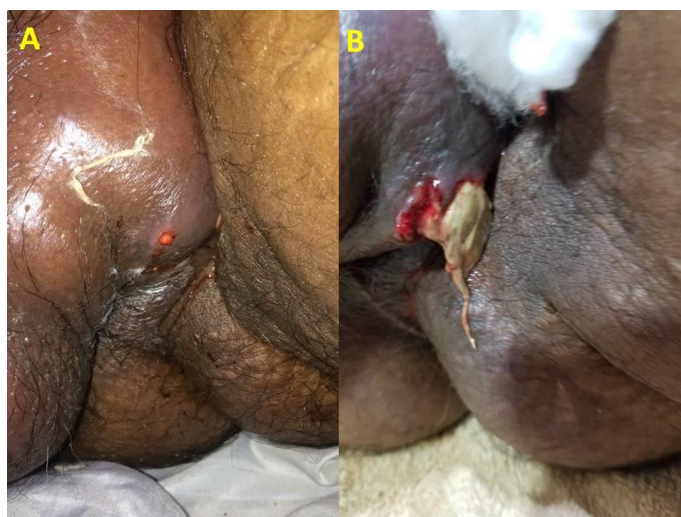


FIGURE 01: A: Lesion with 1 week of evolution, note a point of exit of secretion with edema and phlogistic signs adjacent; B: Lesion with 3 weeks of evolution; note the increase of the exit orifice, with secretion of necro-liquefied substance.

The patient returned to the hospital of origin and was instructed to seek oncological care, but sought emergency medical attention at the Public Hospital of Palmas (HGPP) due to intense pain presented. Based on the clinical history, inspection of the lesion, associated comorbidities and previous patient history, Fournier's Gangrene was identified. Laboratory tests were requested, hospitalization indicated and initiated, and broad-spectrum antibiotics (Meropenem 1g IV 8/8h and Vancomycin 500mg IV 6/6h) for 14 days, cleaning and healing of the lesion with 0.9% saline and Kollagenase.

The patient was submitted to debridement of the lesion on the first day after admission. The procedure was performed without intercurrents. Follow-up with endocrinology was requested for the control of his decompensated diabetes. The surgical wound was treated with a dressing change once a day with silver alginate and Protasan after cleansing with saline solution.

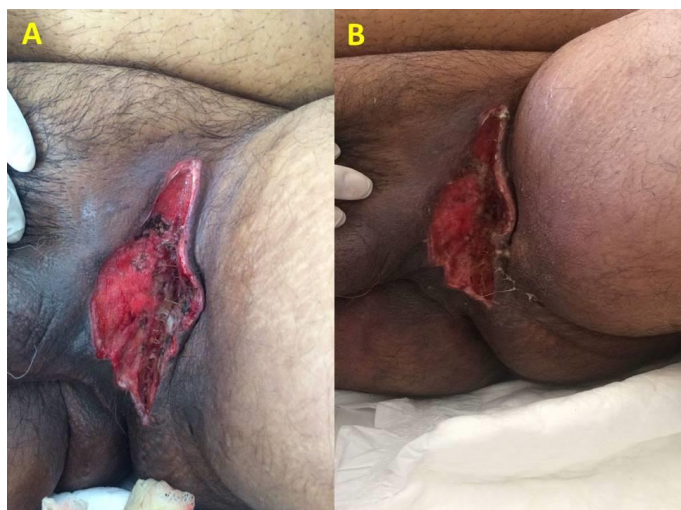


FIGURE 02: Images A and B demonstrate, respectively, the 7th and 8th postoperative period of the first approach. The presence of fibrin in several points with necrosis (darkened points) can be visualized.

On the 8th postoperative day, the patient was taken to the surgical center by the plastic surgery team to close the lesion, but the procedure was not done due to the presence of purulent secretion and necrotic sites in the wound. A new debridement was prescribed and performed the next day. After the latter approach, the surgical wound evolved well, with the absence of secretion and with granulation tissue, making it possible for the reconstruction of the left inguinal region with local flaps of advance to occur after 8 days.

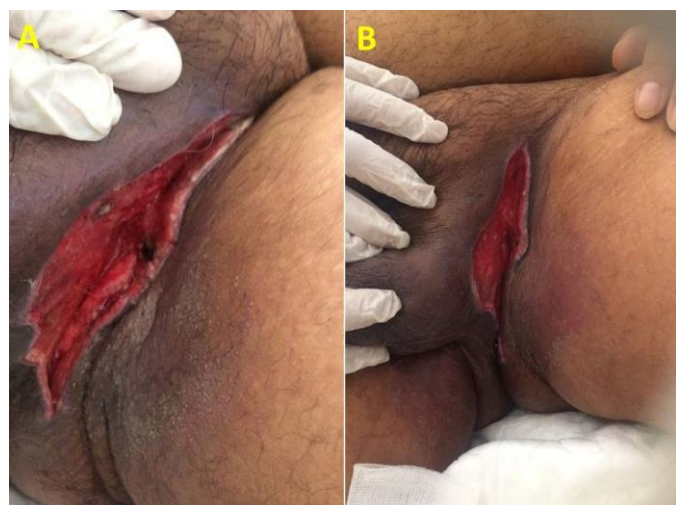

FIGURE 03: Both images represent revision of the surgical approach. In A, note that necrotic tissue and fibrin were removed. In B, photo taken in the 7th PO of revision, immediately before the advance flaps plastic surgery. Note border perfusion, absence of secretion or fibrinoid tissue.

The patient was discharged after 18 days, with clinical improvement and satisfactory operative wound, without phlogistic signs.

CASE DISCUSSION

Based on theoretical reports on the risk group, clinical picture and treatment of Fournier's Gangrene^{1,3,6,7}, a classic case of the disease is found in a patient with recurrence. The previous approach resulted in penile limb amputation 10 years ago. The presence of comorbidities favored the return of the condition.

The patient in question presents three of the predisposing factors: hypertension, Diabetes Mellitus, and obesity. Not only were these comorbidities present, but they were also decompensated^{2,5,6,9}. Generally, an obvious port of entry can be identified. In this case, it was not possible to identify one.

The importance of differential diagnosis is notorious. Initially the lesion was treated for furunculosis. The onset of polymicrobial coverage and surgical debridement was postponed in 30 days, enough time for the infection to progress to a more severe condition.¹

Other possible differential diagnoses of Fournier's Syndrome in its early stages are gangrenous balanitis in diabetics, and among women with diabetic gangrenous vulva, ulcerative and gangrenous forms of inguinal lymphogranulomatosis, soft canker and acute genital ulcers. Even syphilis with necrotic, induced edema, and syphilis ecthymoids can be similar to Fournier's gangrene.⁹

Treatment done with surgery associated with antibiotic therapy and surgical wound care, achieved the expected success, presenting the need for new approaches with debridement, fact corroborated by literature with successful results.^{3,6,7,10}

The present case is an example of how early diagnosis and correct management and support is of essential relevance, for the treatment of Fournier's Gangrene to have an appropriate outcome.

CONCLUSION

Regarding the development and treatment of Fournier's Gangrene, the health professional should be able to differentiate other perianal and pubic lesions from the early stages of Fournier's Gangrene in order to prevent the development of this disease, avoiding complications that can lead to a septic state and even death. Associating the correct treatment and care in the postoperative period is also imperative.

REFERENCES

- Cardoso JB, Féres O .Gangrena de Fournier Medicina (Ribeirão Preto) 2007; 40 (4): 493-9, out./dez. <http://www.fmrp.usp.br/revista>
- HOFFMANN AL; IGLESIAS LF; ROTHBARTH WW; SÍNDROME DE FOURNIER: RELATO DE CASO. Arquivos Catarinenses de Medicina - Volume 38 - Suplemento 01 – 2009
- Santos DR; Roman ULT; Westphalen AP; Lovison K; Neto FACS. Perfil dos pacientes com gangrena de Fournier e sua evolução Clínica. Rev Col Bras Cir. 2018; 45(1):e1430
- Chernyadyev SA, Ufimtseva MA, Vishnevskaya IF, Bochkarev YM, Ushakov AA, Beresneva TA, Galimzyanov FV, Khodakov VV. Fournier's Gangrene: Literature Review and Clinical Cases. Urologia Internationalis 2018;101(1):91-97.
- Mello DF, Júnior AH Scrotal reconstruction with superomedial fasciocutaneous thigh fla. Rev Col Bras Cir. 2018; 45(1):e1389
- El-Sabbagh AH. Coverage of the scrotum after Fournier's gangrene. GMSInterdiscip Plast Reconstr Surg DGPW. 2018;7:Doc01.DOI: 10.3205/iprs000121, URN: urn:nbn:de:0183-iprs0001210
- Moreira DR, Gonçalves ALS, Aucelio RS, Silva KG. Relato de caso: Terapêutica cirúrgica na síndrome de Fournier / Case report: Surgical therapy in Fournier syndrome. Rev Med (São Paulo). 2017 abr.-jun.;96(2):00-00.
- Mello LS, Maluf MM, Nasrala AFS, Henry P. FOURNIER'S SYNDROME. COORTE - Revista Científica do Hospital Santa Rosa. 2014; (4): 63-66
- Chernyadyev SA, Ufimtseva MA, Vishnevskaya IF, Bochkarev YM, Ushakov AA, Beresneva TA, Galimzyanov FV, Khodakov VV. Fournier's Gangrene: Literature Review and Clinical Cases. Urologia Internationalis 2018;101(1):91-97.
- Feng-Shu Chang F.S, Chou C, Hu CY, Huang SH, Suture Technique to Prevent Air Leakage during Negative-Pressure Wound Therapy in Fournier Gangrene.plastique and reconstructive surgery Global Open__2018 Jan 25;6(1):e1650. doi: 10.1097/GOX.0000000000001650. eCollection 2018 Jan.